

# Sonographically Guided Percutaneous Needle Release of the Carpal Tunnel for Treatment of Carpal Tunnel Syndrome

## Preliminary Report

John M. McShane, MD, Samantha Slaff, MS, Judith E. Gold, ScD, Levon N. Nazarian, MD

**Objectives**—The purpose of this study was to evaluate the effectiveness of a novel treatment procedure, sonographically guided percutaneous needle release of the carpal tunnel, for individuals with carpal tunnel syndrome.

**Methods**—Seventeen patients (89% female; mean age, 62 years; SD, 13.6 years) with a clinical diagnosis of carpal tunnel syndrome who had undergone a sonographically guided percutaneous needle release of the carpal tunnel at least 6 months before follow-up evaluation were retrospectively reviewed. At the follow-up evaluation, to ascertain previous and current symptoms as well as functional impairment, the patients filled out a hand diagram and a questionnaire. In addition, medical records were reviewed, and patients were queried regarding complications such as infection or nerve damage. Median nerve sonographic measurements and a physical evaluation were performed on a subset of 13 patients who came to the office for evaluation.

**Results**—Postprocedure sonography showed that patients had a significantly smaller ( $P = .03$ ) cross-sectional area of the median nerve compared to pretreatment values. In addition, patients had significantly fewer symptoms ( $P < .0001$ ), less functional impairment ( $P = .0002$ ), and an improved hand diagram score ( $P < .0001$ ). Postprocedure patients had grip strength that was 12 lb below average ( $\approx 1$  SD below) compared to grip strength norms. However, most patients (84.6%) had negative clinical diagnostic test results for carpal tunnel syndrome, and 86% said they were satisfied with the procedure. There were no procedure-related infections or nerve injuries.

**Conclusions**—Of the patients with carpal tunnel syndrome who agreed to participate in this study, most had favorable symptomatic and functional outcomes. Sonographically guided percutaneous needle release of the carpal tunnel may be an alternative option to traditional surgical treatment of carpal tunnel syndrome.

**Key Words**—carpal tunnel; percutaneous release; sonography

Received January 30, 2012, from McShane Sports Medicine, Villanova, Pennsylvania USA (J.M.M.); Department of Public Health, Temple University, Philadelphia, Pennsylvania USA (S.S., J.E.G.); and Department of Radiology, Thomas Jefferson University Hospital, Philadelphia, Pennsylvania USA (L.N.N.). Revision requested February 22, 2012. Revised manuscript accepted for publication March 13, 2012.

We thank Frank McCabe, PT (McCabe and Brady Physical Therapy, Warminster, PA), and Valerie Brill, PT (Excel Physical Therapy, Villanova, PA), for assistance.

Guest Editor: Mark E. Lockhart, MD, MPH.

Address correspondence to John M. McShane, MD, McShane Sports Medicine, 734 E Lancaster Ave, Villanova, PA 19085 USA.

E-mail: [bjmshane@pol.net](mailto:bjmshane@pol.net)

Carpal tunnel syndrome is the most common compressive neuropathy of the upper extremity.<sup>1</sup> It is estimated that 1 million adults in the United States have carpal tunnel syndrome annually, and there is a 10% risk of developing carpal tunnel syndrome in one's lifetime.<sup>1,2</sup> Carpal tunnel syndrome is caused by compression of the median nerve under the transverse carpal ligament at the base of the palm.<sup>3</sup> The condition results in a variety of symptoms, including pain, paresthesia, numbness, sleep disturbance, and weakness of the hand. Surgical treatment for carpal tunnel syndrome is the most frequent surgery of the hand and wrist, with nearly 500,000 carpal tunnel releases performed annually in the United States.<sup>4</sup>

There are a variety of treatment methods for carpal tunnel syndrome. Nonsurgical treatments include splinting the hand and wrist, physical therapy, and injection of a corticosteroid. The choice of treatment depends on the severity, the duration of symptoms, and patient preferences.<sup>5</sup> If nonsurgical methods are not helpful in alleviating carpal tunnel syndrome symptoms, then a surgical release is the ultimate step. Surgery involves dividing the transverse carpal ligament to relieve pressure on the median nerve. Surgical procedures have high success rates.<sup>5</sup> After surgical release of the transverse carpal ligament, the time it takes to return to work or normal daily activities varies from 5 days to 4 weeks.<sup>5</sup>

Surgical techniques for dividing the transverse carpal ligament commonly involve either an “open” technique or an endoscopic technique and usually require an operating room setting along with either sedation or general anesthesia. While performing less invasive endoscopic techniques, some authors have described using diagnostic sonography as an aid to help guide the procedure.<sup>6</sup>

To minimize the potential morbidity of surgery, we have developed a sonographically guided percutaneous needle technique to decompress the median nerve. This technique is office based and uses only a local anesthetic. This article serves as a retrospective review of our experience with this technique. The purpose of our analysis was to evaluate clinical outcomes and complications of this procedure. In addition, we compared median nerve morphologic characteristics, as determined by sonography, both before and after the procedure, to determine whether any changes in the nerve structure could be identified.

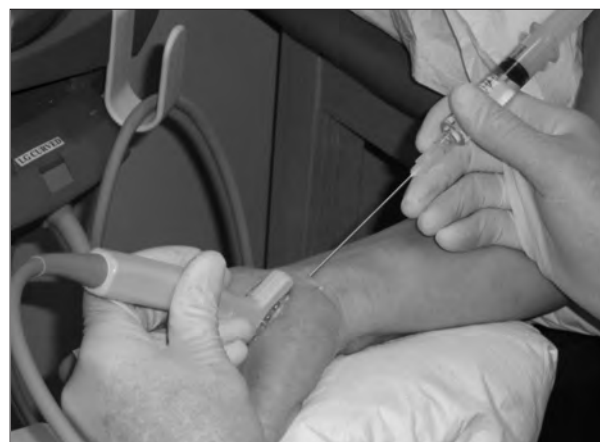## Materials and Methods

This retrospective study was initiated after approval of the Temple University Institutional Review Board and was designed to assess outcomes of sonographically guided percutaneous needle release of the carpal tunnel. All participants eligible for the study were patients of one of the authors (J.M.M.) and had a diagnosis of carpal tunnel syndrome by standard clinical criteria, including history, physical examination, and sonographic evaluation. Although not all patients had electromyographic studies performed previously, of those who did, the studies were all consistent with the diagnosis of carpal tunnel syndrome. Each patient was considered a surgical candidate.

All patients underwent a sonographically guided percutaneous needle release of the carpal tunnel, which was performed by J.M.M. at least 6 months before September 1, 2009. The procedure was performed in the follow-

ing manner: With the patient supine on an examining table and the affected hand positioned to the side with the palm up, the median nerve was visualized using a 13-MHz multifrequency linear array ultrasound transducer (MicroMaxx; SonoSite, Inc, Bothell, WA). After wiping the skin with ethyl alcohol, a 25-gauge, 1.5-in hypodermic needle was introduced under the skin at about the level of the proximal flexor crease of the wrist. Using continuous sonographic guidance, 5 to 10 mL of a solution of 1% lidocaine and 8.4% sodium bicarbonate (in a ratio of 10:1) was injected as the needle was guided down to the transverse carpal ligament. The needle was kept superficial to, and slightly to the ulnar side of, the median nerve. Once the ligament was adequately anesthetized, the needle was withdrawn, and after wiping the skin again with alcohol, an 18-gauge spinal needle was introduced through the same entry point (Figure 1). Under continuous sonographic guidance, the needle was used to repeatedly perforate the transverse carpal ligament in a direction parallel to the median nerve. Again, the needle was kept superficial to, and slightly to the ulnar side of, the median nerve (Figure 2). Care was taken to avoid any injury to the nerve or vascular structures. Once the needle was able to be passed easily through the ligament, signifying that it had been adequately fenestrated, the needle was placed within the substance of the ligament, and the syringe was changed. The ligament was then infiltrated with a solution of 0.5 mL of betamethasone (40 mg/mL) and 2 mL of 1% lidocaine. The needle was then withdrawn, and a small adhesive bandage was placed over the needle entry point. The patients were then instructed to perform nerve and tendon glides and were sent to physical therapy, which began the next day. All patients were seen again in the office 2 weeks after the procedure.

**Figure 1.** Needle placement for release of the transverse carpal ligament.



To avoid confounding by a condition that causes symptoms similar to carpal tunnel syndrome, patients were deemed ineligible for the study if they had magnetic resonance imaging or electromyographic results that confirmed a diagnosis of cervical radiculopathy affecting the same side as their hand that received the procedure. Eligible patients were contacted by mail and by telephone to solicit their interest in participating in the study. If, after 1 letter and 3 phone calls, an individual could not be contacted, he or she was considered lost to follow-up. Those individuals who were able to be contacted and who were willing to participate in the study were scheduled for an appointment to return to the office for a follow-up evaluation. If they were unable to come back to the office, they were asked to fill out a mailed questionnaire. This same questionnaire was filled out by those patients who returned to the office for evaluation.

#### Examination Procedures

All participants signed a written consent form at the time of the follow-up examination. Physical evaluations were performed by 1 of 2 licensed physical therapists. Sonographic evaluations were performed by a radiologist with 15 years of experience in musculoskeletal sonography (L.N.N.). All physical and sonographic evaluations were performed on both hands, and the physical thera-

pists and radiologist were blinded as to which hand had received treatment for carpal tunnel syndrome. In addition, at this time, medical records were reviewed, and patients were queried regarding complications such as infection or nerve damage.

#### Sonographic Measurements

Sonographic measurements of the median nerve were taken while patients were seated or lying down with the hand resting in a supinated position on an examining table and the wrist supported by a rolled-up towel beneath it. Using the 13-MHz linear array transducer described above, axial views of the median nerve were obtained. Using the ellipse function on a frozen image, the cross-sectional area at the median nerve was measured at the distal wrist crease just proximal to the carpal tunnel. Next, on longitudinal views, anteroposterior measurements of the median nerve diameter were performed using electronic on-screen calipers just proximal to the tunnel where the nerve was thickest (proximal diameter) and within the carpal tunnel where the nerve was most flattened (distal diameter). Before undergoing the needle release procedure, these measurements had been taken on all patients by the author who performed the procedure (J.M.M.).

#### Physical Measurements

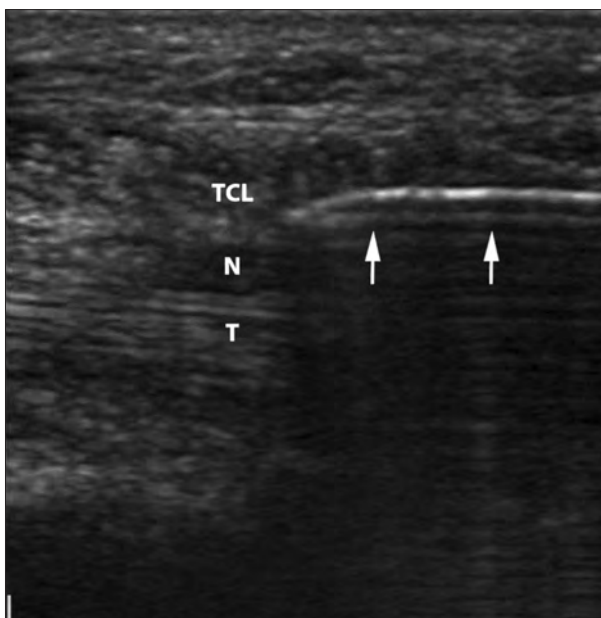
After the sonographic measurements, patients underwent a physical evaluation that assessed responses to tests used in diagnosing carpal tunnel syndrome. The Phalen test, Tinel test, upper limb tension test, carpal compression test, and signs of atrophy were evaluated.

In the Phalen test, the examiner asked the patient to flex the wrist maximally and hold that position for 1 minute. A positive result was indicated by production of paresthesia anywhere within the median nerve distribution in the thumb, index and long fingers, and lateral half of the ring finger.<sup>3</sup>

The Tinel test was performed by tapping gently on the median nerve on the palmar side of the patient's wrist 3 times. A positive result was indicated by production of a tingling sensation during each tap.

The upper limb tension test was performed by first tilting the patient's head laterally to the side opposite that being tested. The shoulder girdle of the side being tested was then depressed and stabilized, and the elbow was flexed to 90° and the shoulder abducted to 90° in the coronal plane. The shoulder was then externally rotated, and the forearm was fully supinated, while the wrist, fingers, and thumb were extended. The elbow was then slowly extended, and the examiner assessed dural mobility and restrictions.<sup>7</sup> The patient was questioned to determine

**Figure 2.** Longitudinal sonogram of the median nerve within the carpal tunnel, with the needle in the transverse carpal ligament, superficial to the median nerve. Arrows indicate the needle; N, median nerve; T, flexor tendon; and TCL, transverse carpal ligament.



whether there was any production of tightness at the elbow or pain, tingling, or numbness in the wrist or hand. A positive result was indicated by reproduction of symptoms and limited dural mobility compared to the opposite upper extremity.

The carpal compression test was done by applying firm pressure on the palm over the median nerve for up to 30 seconds. A positive result was indicated by production of paresthesia in the hand or fingers.

Atrophy was checked at the thenar eminence of the hand (thumb musculature on the palm side of the hand). The physical therapist looked for differences bilaterally. A positive result was indicated by flattening or wasting of the thenar muscles.

Grip strength and thumb abduction tests were also conducted. Grip strength was assessed using a Jamar dynamometer (Sammons Preston Rolyan, Bolingbrook, IL). Participants were positioned with the arm fully extended and instructed to squeeze as hard as possible. The dynamometer records the maximum pounds of force exerted. Three repetitions of the test were averaged.

Thumb abduction was assessed with patients seated and the palm in a supinated position. The thumb was then abducted against the resistance of the tester. A manual muscle testing scale was used to grade their performance. This scale ranged from 0 to 5, with 0 indicating that they were not capable of performing this test and 5 indicating that they were able to perform this test against full resistance.

#### *Symptom Questionnaire*

After the physical examination, patients filled out a 4-part questionnaire, which included the following: (1) a symptom assessment, (2) a functional impairment grid, similar to the DASH (disabilities of the arm, shoulder, and hand),<sup>8</sup> (3) a carpal tunnel syndrome hand diagram,<sup>9</sup> and (4) patient satisfaction items. On the symptom questionnaire, the choice of possible responses ranged from 1, indicating no symptoms, to 5, indicating the most intense symptoms. Items on the symptom questionnaire included queries regarding the severity of hand or wrist pain at night, frequency of being awakened during the night due to hand or wrist pain, frequency of hand or wrist pain during the day, length of pain episodes during the day, sensations and severity of numbness in the hand, weakness in the hand or wrist, tingling in the hand, frequency of being awakened during the night due to numbness or tingling, and sensations of coldness in the hand.

Similar to the symptom questionnaire, response choices on the functional impairment assessment ranged from 1, indicating no functional impairment, to 5, indicating maximum

functional impairment. The functional impairment grid assessed tasks including writing, buttoning clothing, holding a book, gripping the telephone, opening jars, household chores, carrying grocery bags, and grasping small objects. Symptoms before the procedure and current symptoms were assessed for all 4 parts of the evaluation.

#### *Patient Satisfaction Assessment*

Patients were asked on a scale of 1 to 10, 1 indicating least satisfied and 10 indicating most satisfied, how satisfied they were with the procedure and its results. Patients were also asked a yes/no question about whether they would recommend this procedure to a family member or friend who had carpal tunnel syndrome.

#### *Variable Construction*

A symptom index was created by totaling the scores of each response on the questionnaire (possible range of scores, 11–55). A functional impairment index variable was created by summing the response score for the function impairment grid as well as the last question of the symptom questionnaire regarding grasping (possible range of scores, 8–40). The results of the hand diagram were coded according to the methods described by Katz and Stirrat.<sup>9</sup> The coding is denoted as follows: 4, classic; 3, probable; 2, possible; and 1, unlikely carpal tunnel syndrome.

For each of these variables, we assessed measurements for the patients both before and after the procedure. If we did not have both measures for a specific patient, that variable for that person was eliminated from analysis (ie, if someone did not fill out the hand diagram for both before and after the procedure, the hand diagram analysis was eliminated for that particular patient). If patients had the procedure performed on both hands, only the first hand operated on was used in evaluating the data.

Our grip strength measurements were compared to grip strength norms of Mathiowetz et al.<sup>10</sup> In that study, the norms were based on sex, age, and hand. The differences between the patients' grip strength and the grip strength norms matched by sex, age, and hand were calculated. The number of standard deviations above or below the norm for that person's grip strength was then calculated by dividing the difference in scores by the standard deviation for the grip strength norm.

#### *Statistical Analysis*

For each variable, a Wilcoxon signed rank test was used to compare variable medians before and after the procedure. A 1-sided test was used in evaluating the cross-sectional area, functional impairment index, symptom index, and

hand diagram, whereas a 2-sided test was used in evaluating the proximal and distal diameter measurements.  $P \leq .05$  was regarded as statistically significant. Statistical analyses were completed using SAS version 9.2 software (SAS Institute Inc, Cary, NC).

## Results

Thirty-eight patients were reviewed for eligibility to participate in the study. Of those, 36 were deemed eligible to participate and were contacted. Eleven patients (29%) did not respond to multiple attempts to contact them; 2 (5%) declined to participate; 14 (37%) agreed to come to the office for an evaluation; and 9 (24%) agreed to fill out mailed questionnaires. Of the 14 patients who agreed to return to the office, 1 did not return for the scheduled visit, leaving 13 patients who came into the office for evaluation. Among the 9 participants who agreed to fill out questionnaires, 5 were completed and returned, and 4 were not returned. In total, there were 18 participants involved in the study, yielding a response rate of 47%.

Of the 18 questionnaires that were completed, 1 was judged unreliable because of inconsistent responses and eliminated, bringing the total number of patients analyzed to 17. Of the 17 participants in the study, 89% were female, with a mean age of 62 years (SD, 13.6 years), and a mean time since sonographically guided percutaneous release of the carpal tunnel of 25 months (SD, 9.2 months). The average age of nonparticipants was 64 years (SD, 12.2 years), and 85% of those who did not respond were female.

## Sonography

The cross-sectional area of the median nerve had a statistically significant decrease in size, measuring a median of  $0.15 \text{ cm}^2$  before the procedure (Figure 3A) compared with  $0.14 \text{ cm}^2$  after the procedure (Figure 3B;  $P = .039$ ; Table 1). The proximal diameter of the median nerve had no significant change ( $P = .196$ ) when comparing measurements before (Figure 4A) and after (Figure 4B) the procedure. In contrast, the distal diameter of the median nerve increased in size significantly from a median of  $0.14 \text{ cm}$  before the procedure (Figure 5A) to  $0.21 \text{ cm}$  after the procedure (Figure 5B;  $P = .049$ ; Table 1).

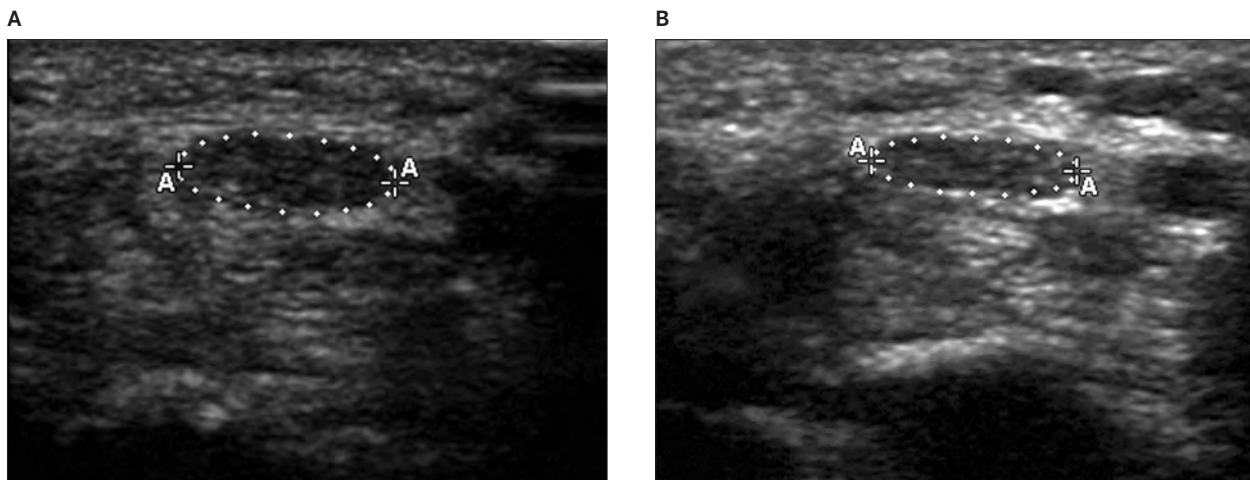
## Symptoms

The functional impairment index measure was found to have decreased from an average value of 20 before the procedure to an average value of 10 after the procedure ( $P = .0009$ ), indicating better functioning after the procedure. The symptom index also had a statistically significant ( $P < .0001$ ) decrease from a median of 35 before the procedure to 12 after the procedure. Finally, the hand diagram score showed a significant change from a median of 4 before the procedure to 1 after the procedure, indicating a decreased likelihood of patients having carpal tunnel syndrome ( $P = .0004$ ).

## Physical Examination Findings

The grip strength for patients after the procedure was on average 12 lb less than the grip strength norm, based on sex, age, and hand. Five of thirteen (38%) patients had grip strengths that were 2 SDs below the grip strength norms

**Figure 3.** **A**, Transverse sonogram of the median nerve at the distal wrist crease before percutaneous needle release. The cross-sectional area (A) of the median nerve measures  $0.18 \text{ cm}^2$ . **B**, Transverse sonogram of the median nerve at the distal wrist crease 20 months after percutaneous needle release. The cross-sectional area of the median nerve has decreased slightly to  $0.14 \text{ cm}^2$ .

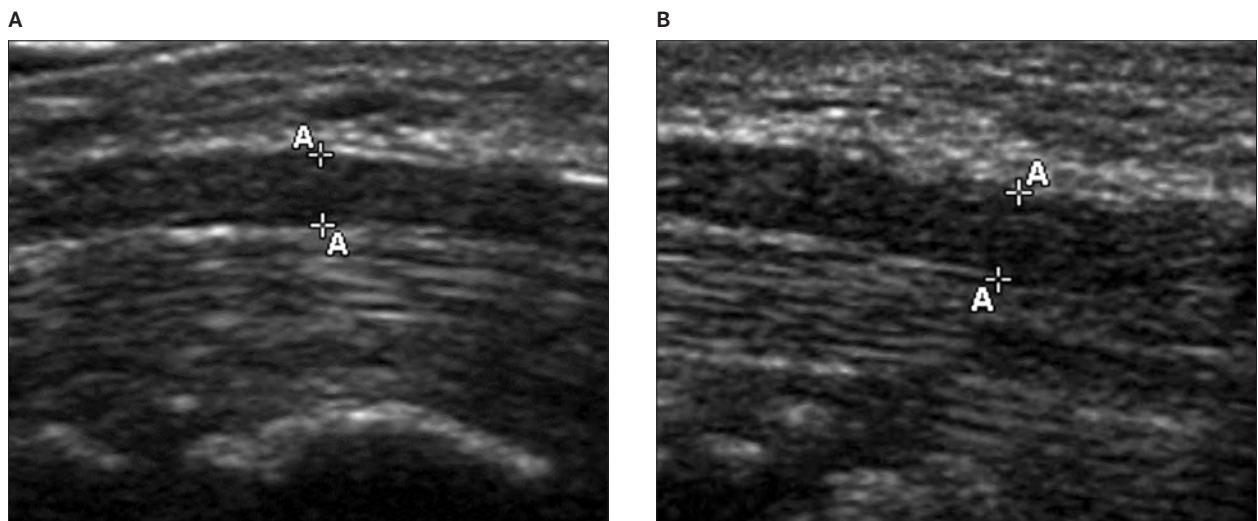


(Table 2). At the time of follow up evaluation, 1 of the 13 patients had positive Phalen test results, and 1 had positive upper limb tension test results. Two of the patients had positive Tinel test results, and 2 had a positive carpal compression test results. Four of the 13 patients had atrophy. Fifteen of 18 patients who filled out questionnaires (83%) would recommend this procedure to others. On a scale from 1 (lowest) to 10 (highest) regarding satisfaction with the procedure, the average score was 8.6 (SD, 2.4).

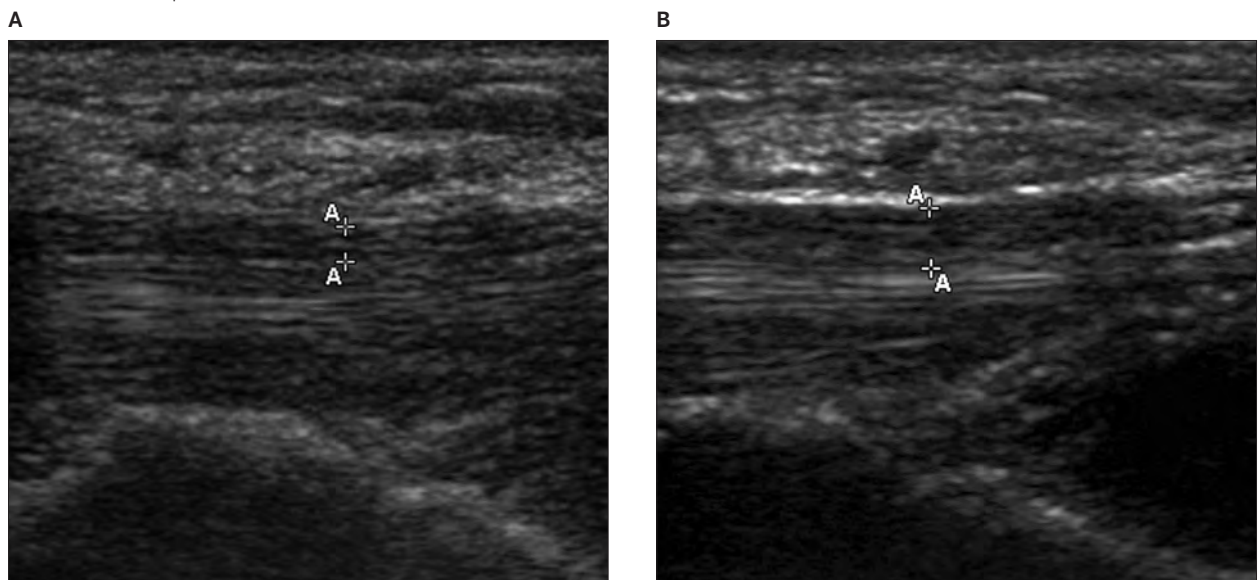
## Discussion

Our results indicate that patients had fewer signs and symptoms of carpal tunnel syndrome and had less compression of the median nerve, as seen on sonography, after undergoing sonographically guided percutaneous needle release of the carpal tunnel. Eighty-six percent of patients were satisfied with the procedure. Less than 16% of patients tested positive for signs of carpal tunnel syndrome

**Figure 4. A.** Longitudinal sonogram of the median nerve proximal to the carpal tunnel before percutaneous needle release. The anteroposterior dimension (A) of the nerve measures 0.27 cm. **B.** Longitudinal sonogram of the median nerve proximal to the carpal tunnel 20 months after percutaneous needle release. The anteroposterior dimension of the nerve has decreased slightly to 0.23 cm.



**Figure 5. A.** Longitudinal sonogram of the median nerve within the carpal tunnel before percutaneous needle release. The anteroposterior dimension (A) of the nerve measures 0.14 cm. **B.** Longitudinal sonogram of the median nerve within the carpal 20 months after percutaneous needle release. The anteroposterior dimension of the nerve has increased to 0.25 cm.



after the procedure. Despite the clinical improvement, 31% of patients still had atrophy in their hand, and 38% had below-average grip strength.

There were some important limitations in this study. One was incomplete data on patients before the procedure. Hence, we lacked the ability to compare preprocedure and postprocedure results for physical examination carpal tunnel syndrome tests. Also, it would have been interesting to see the results of preprocedure and postprocedure electrodiagnostic studies. In addition, symptoms and functional impairment were assessed using retrospective recall, which may be subject to bias. Patients may have over-recalled their prior symptoms and functional impairment, which would have yielded more favorable results than was truly the case. However, the literature regarding recall of symptoms has shown that average pain recall is a dependable measure, and pain is more often under-reported rather than over-reported, unless the person is still currently in pain.<sup>11-13</sup> In this study, most patients were free of symptoms at the time of evaluation.

Finally, with a response rate of just less than 50%, selection bias does come into play, and we may not have had a representative sample of patients who received the treatment. Although nonparticipants were similar based on age and gender, we could not compare participants and nonparticipants on the basis of the severity of symptoms or satisfaction with the procedure. It may be that the patients who did not respond did not have a severe case of carpal tunnel syndrome, and only the patients with the most severe cases before the procedure agreed to participate. If this scenario occurred, our results would be biased toward a favorable outcome because only those patients with severe carpal tunnel syndrome would gain the most benefit in alleviating their symptoms. Conversely, if only those with mild symptoms of carpal tunnel syndrome participated in this study, it may have biased our results toward the null because those patients would have had a limited range of potential symptom improvement. It could also be the case that only those who were most pleased with the procedure agreed to participate, which would have heavily biased our

**Table 1.** Median and Interquartile Range for Median Nerve Area, Proximal Diameter, Distal Diameter, Functional Impairment Index, Symptom Index, and Hand Diagram Carpal Tunnel Syndrome Score

Parameter	n	Before Procedure		After Procedure		Signed Rank	P <sup>a</sup>
		Median	IQR	Median	IQR		
Median nerve area, cm <sup>2</sup>	11	0.15	0.05	0.14	0.05	175	.039
Proximal diameter, cm	11	0.26	0.07	0.22	0.07	5.0	.196
Distal diameter, cm	10	0.14	0.04	0.21	0.07	-19.5	.049
Function impairment index	16	20.0	6.5	10.5	4.0	59.0	.0009
Symptom index	17	35.0	8.0	12.0	4.0	76.5	<.0001
Hand diagram score	16	4.0	1.0	1.0	1.0	51.0	.0004

IQR indicates interquartile range.

<sup>a</sup>Wilcoxon signed rank test. All *t* tests were 1 sided except proximal and distal diameter measurements, which were 2 sided.

**Table 2.** Grip Strength Comparison Between Patients and Norms Matched by Sex, Age, and Hand

Patient	Grip Strength, lb				
	Patient	Norm	Norm SD	Patient - Norm	SD Below/Above Norm
1	27	56.0	12.7	-29	-2.3
2	61	65.8	11.6	-5	-0.4
3	30	49.6	9.7	-20	-2.0
4	39	91.1	20.6	-52	-2.5
5	108	76.8	20.3	31	1.5
6	40	42.6	11.0	-3	-0.2
7	42	65.8	11.6	-24	-2.1
8	39	42.6	11.0	-4	-0.3
9	58	45.7	10.1	12	1.2
10	34	37.6	8.9	-4	-0.4
11	39	55.1	10.1	-16	-1.6
12	48	65.8	11.6	-18	-1.5
13	43	70.4	13.5	-27	-2.0

results in favor of this procedure. Any type of surgical treatment of carpal tunnel syndrome is a last-resort option after all other less invasive procedures are attempted. Because both participants and nonparticipants underwent the procedure, it is likely that all patients receiving this treatment had a relatively severe case of carpal tunnel syndrome. Thus, we assume that the severity of carpal tunnel syndrome was comparable between study participants and nonparticipants.

Wang et al<sup>14</sup> found that patients who had bilateral open carpal tunnel release had a mean time out of work of 2.6 weeks, and 96% were satisfied with their procedure. Hansen et al<sup>15</sup> found that patients had an average sick leave of 19.8 days, with 24% of patients being out longer than 21 days after endoscopic carpal tunnel release. Another study found reported days out of work ranging anywhere from 1 to 88 days after carpal tunnel release.<sup>16</sup>

Unfortunately, our study did not directly measure the number of days until patients returned to work after the procedure. However, according to our standard practice, patients are expected to return to normal activities of daily living and to return to work anywhere from 1 to 4 days after sonographically guided percutaneous needle release. Thus, our less invasive procedure likely leads to a shorter recovery time than traditional open or endoscopic carpal tunnel releases.

The median nerve cross-sectional area results were consistent with those found by Abicalaf et al,<sup>17</sup> showing a smaller cross-sectional area after surgical releases of the carpal tunnel. There is little to no research with regard to proximal and distal diameter measurements examined both before and after surgical intervention.

Badger et al<sup>18</sup> found that after open carpal tunnel releases, patients had significantly decreased symptoms of carpal tunnel syndrome ( $P < .0001$ ) as well as improved functional impairment ( $P < .0001$ ), similar to the results of our study. Thurston and Lam<sup>19</sup> found that after open carpal tunnel release, 70% of patients reported a reduction in severity of pain; 78% of hands had reduced paresthesia; and 77% had reduced numbness. Forty-nine percent of patients had decreases in all 3 of the symptoms after surgery, and 10% of hands were still testing positive for either the Phalen or Tinel test.

Thurston and Lam<sup>19</sup> also found that 93% of this population had normal grip strength after the surgery. Bednarski et al<sup>20</sup> found that 12 months after open carpal tunnel release, patients had a grip strength that was 138% increased over their grip strength before surgery. This increase in grip strength was found to be statistically significant. Olsen and Knudson<sup>21</sup> found that there was a significant decrease in grip strength immediately after open carpal tunnel release

surgery, and there was a nonsignificant increase in grip strength by 25 weeks after surgery. Postsurgical studies also show a mix in results regarding grip strength after surgery. Because of our lack of complete data on grip strength before the procedure, we cannot draw conclusions about an increase or decrease in strength. However, we did find that 62% of our population had grip strength in the normal range after the procedure.

The results of this study show that sonographically guided percutaneous release of the carpal tunnel has results that are similar to results found using traditional carpal tunnel surgery. Most outcomes of this procedure were favorable. Although certain measures such as grip strength and diagnostic test results (Phalen, Tinel, carpal compression, and upper limb tension tests) were considered abnormal for some patients after the procedure, overall, most of the sample had favorable outcomes. In addition to its positive effect on symptoms, future analysis will clarify the question of how long patients undergoing this procedure will need to be out of work.

In conclusion, the results of this study indicate a post-procedure decrease in symptoms of carpal tunnel syndrome as well as decreased functional impairment in patients who underwent sonographically guided percutaneous needle release of the carpal tunnel. The major implication of this study is that sonographically guided percutaneous release of the carpal tunnel may be a viable alternative to traditional surgical releases. More studies with larger sample sizes are needed to further evaluate the effectiveness of this treatment and its outcomes compared to conventional surgical release.

## References

1. Aroori S, Spence RA. Carpal tunnel syndrome. *Ulster Med J* 2008; 77:6–17.
2. Goodyear-Smith F, Arroll B. What can family physicians offer patients with carpal tunnel syndrome other than surgery? A systematic review of nonsurgical management. *Ann Fam Med* 2004; 2:267–273.
3. Calliet R. *Soft Tissue Pain and Disability*. Philadelphia, PA: FA Davis Co; 1996.
4. Palmer DH, Hanrahan LP. Social and economic costs of carpal tunnel surgery. In: American Academy of Orthopaedic Surgeons (eds). *Instructional Course Lectures of the American Academy of Orthopaedic Surgeons*. Vol 44. St Louis, MO: CV Mosby Co; 1995:167–172.
5. Uchiyama S, Itsubo T, Nakamura K, Kato H, Yasutomi T, Momose T. Current concepts of carpal tunnel syndrome: pathophysiology, treatment, and evaluation. *J Orthop Sci* 2010; 15:1–13.
6. Rowe NM, Michaels J V, Soltanian H, Dobryansky M, Peimer CA, Gurtner GC. Sonographically guided percutaneous carpal tunnel release: an anatomic and cadaveric study. *Ann Plast Surg* 2005; 55:52–56.



7. Butler D. Chapter 8. In: *Mobilisation of the Nervous System*. London, England: Churchill Livingstone, Longman Group UK Ltd; 1991:148–151.
8. Hudak PL, Amadio PC, Bombardier C. Development of an upper extremity outcome measure: the DASH (disabilities of the arm, shoulder, and hand) [corrected]. The Upper Extremity Collaborative Group (UECG). *Am J Ind Med* 1996; 29:602–608.
9. Katz JN, Stirrat CD. A self-administered hand diagram for the diagnosis of carpal tunnel syndrome. *J Hand Surg Am* 1990; 15:360–363.
10. Mathiowetz V, Kashman N, Volland G, Weber K, Dowe M, Rogers S. Grip and pinch strength: normative data for adults. *Arch Phys Med Rehabil* 1985; 66:69–74.
11. Miranda H, Gold JE, Gore R, Punnett L. Recall of prior musculoskeletal pain. *Scand J Work Environ Health* 2006; 32:294–299.
12. Brauer C, Thomsen JF, Loft IP, Mikkelsen S. Can we rely on retrospective pain assessments? *Am J Epidemiol* 2003; 157:552–557.
13. Hahn T. Criterion related validity of self-reported knee symptoms among athletes. *Scand J Med Sci Sports* 2002; 12:282–287.
14. Wang AA, Hutchinson DT, Vanderhooff JE. Bilateral simultaneous open carpal tunnel release: a prospective study of postoperative activities of daily living and patient satisfaction. *J Hand Surg Am* 2003; 28:845–848.
15. Hansen TB, Dalsgaard J, Meldgaard A, Larsen KA. A prospective study of prognostic factors for duration of sick leave after endoscopic carpal tunnel release. *BMC Musculoskelet Disord* 2009; 10:144. doi:10.1186/1471-2474-10-144.
16. Ratzon N, Schejter-Margalit T, Froom P. Time to return to work and surgeons' recommendations after carpal tunnel release. *Occup Med (Lond)* 2006; 56:46–50.
17. Abicalaf CA, de Barros N, Sernik RA, et al. Ultrasound evaluation of patients with carpal tunnel syndrome before and after endoscopic release of the transverse carpal ligament. *Clin Radiol* 2007; 62:891–894.
18. Badger SA, O'Donnell ME, Sherigar JM, Connelly P, Spence RAJ. Open carpal tunnel release: still a safe and effective operation. *Ulster Med J* 2008; 77:22–24.
19. Thurston A, Lam N. Results of open carpal tunnel release: a comprehensive, retrospective study of 188 hands. *Aust NZ J Surg* 1997; 67:283–288.
20. Bednarski M, Zyluk A, Zyluk B. Changes of grip and pinch strength after carpal tunnel release [in Polish]. *Chir Narzadow Ruchu Ortop Pol* 2005; 70:21–26.
21. Olsen KM, Knudson DV. Change in strength and dexterity after open carpal tunnel release. *Int J Sports Med* 2001; 22:301–303.